

Spatial cognition: evidence from visual neglect

Peter W. Halligan¹, Gereon R. Fink², John C. Marshall³ and Giuseppe Vallar⁴

¹School of Psychology, Cardiff University, PO Box 901, Cardiff, CF10 3YG, UK

²Institute of Medicine, Research Centre Jülich, 52425 Jülich; and Neurology Department, RWTH, Aachen, Germany

³Neuropsychology Unit, University Department of Clinical Neurology, Radcliffe Infirmary, Oxford, OX2 6HE, UK

⁴Università degli studi di Milano-Bicocca, Laboratorio di Neuroimaging, Cognitive & Cliniche, and Dipartimento di Psicologia Edificio U6, Piazza dell'Ateneo Nuovo 1, 20126-Milano, Italy

Recent work on human attention and representational systems has benefited from a growing interplay between research on normal attention and neuropsychological disorders such as visual neglect. Research over the past 30 years has convincingly shown that, far from being a unitary condition, neglect is a protean disorder whose symptoms can selectively affect different sensory modalities, cognitive processes, spatial domains and coordinate systems. These clinical findings, together with those of functional neuroimaging, have increased knowledge about the anatomical and functional architecture of normal subsystems involved in spatial cognition. We provide a selective overview of how recent investigations of visual neglect are beginning to elucidate the underlying structure of spatial processes and mental representations.

Once considered a unitary syndrome, it is now accepted that visuospatial neglect results from the interplay of damage to several different cognitive processes [1,2]. Even within such relatively simple tasks as copying or spontaneous drawing, patients show many qualitatively distinct patterns of omission and distortion in 'left' space [3].

Deficits of attention, intention, global-local processing, spatial memory and mental representation can all contribute to the clinical picture of neglect, which accordingly cannot be traced back to the disruption of a single supramodal process [1,4]. Many of the symptoms traditionally ascribed to left neglect share little in common other than a contra-lesional gradient of increasing impairment, with comparatively well -preserved performance on the ipsilesional (right) side of space [1,5].

Although characterising and remediating the clinical condition [1,2,5] are clearly crucial, the primary interest for cognitive neuroscience is how conditions such as visual neglect can inform existing cognitive theory and functional anatomy. That an abnormal bias towards one side of space can exist in the absence of contralateral peripheral sensory or motor loss (e.g. visual field losses or hemi-paralysis) suggests that impairment to higher level processes must be involved. The standard approach taken by cognitive neuropsychology characterises complex mental processes as information-processing systems with separate but

interconnected components. Some of the information-processing stages involved in visual object recognition (see Fig. 1) illustrate the potential levels and links where lateralised deficits can arise after brain damage.

This model charts the processing routes from pre-attentive assignment of simple structural features (i.e. without the need for focused attention and conscious awareness) to post-attentive integration of local and global processing (involving selective attention and conscious awareness) and the assignment of relevant spatial frames of reference prior to recognition and naming.

Systematic testing of patients with visual neglect over

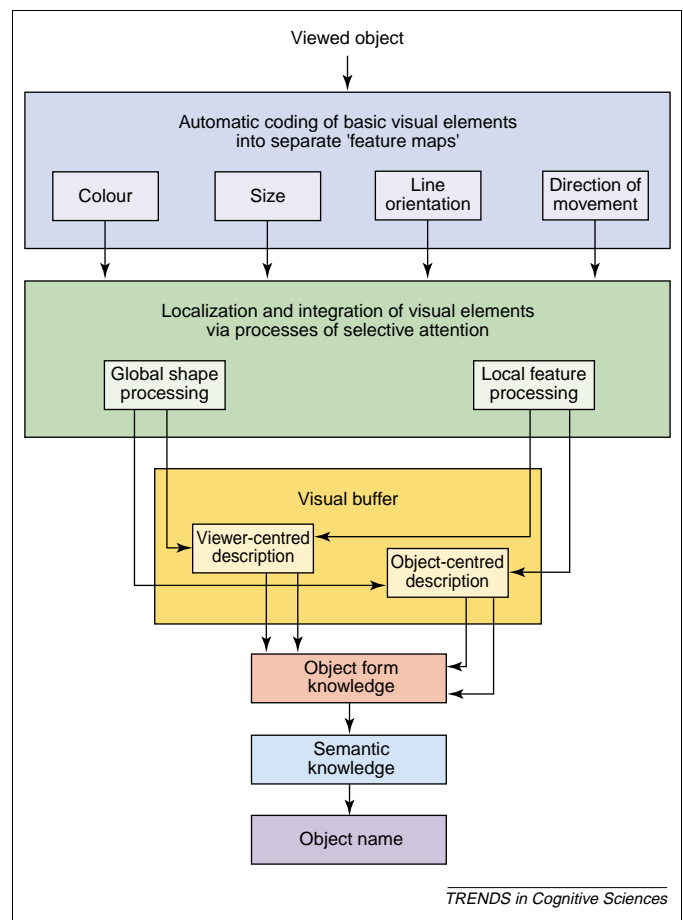


Fig. 1. Schematic information-processing model of object recognition. (Adapted with permission from Ref. [66])

Corresponding author: Peter W. Halligan (HalliganPW@cardiff.ac.uk).

the past two decades has produced significant insights into the structures and stages whereby information is extracted from visual arrays. These include:

Selective preservation of pre-attentive processes

Investigations of visual neglect have contributed to the classic debate regarding the processing locus of attentional selection [2,6]. According to the late selection view, pre-attentive analysis of the whole scene takes place up to and including initial recognition of the object. However, early selection accounts argue that only basic perceptual processing takes place pre-attentively and focal attention is necessary for object recognition. The question thus hinges on the cognitive level to which stimuli are pre-attentively processed. Studies of visual neglect have shown that, dependent on the relevance of the stimuli, pre-attentive processing up to the level of meaning can take place in the 'neglected' field without conscious awareness [1,2,7,8]. Even on line bisection (a traditional clinical measure), patients with severe left neglect can show implicit sensitivity to many figural characteristics of the stimulus display [9] confirming that pre-attentive visual capacities can influence explicit visuo-motor performance. This pre-attentive processing in neglect even extends to the appreciation of subjective illusions of length [10].

Spatial reference frames

The brain codes visual inputs with respect to some spatial frame of reference. These frames provide the basis for attributing up-down, and left-right to spatial arrays and can be based on the direction of the viewer's gaze (egocentric) and/or intrinsic characteristics of an object or its environment (allocentric) (see also Box 1):

Egocentric: Egocentric space coding (with respect to different viewer-centred frames of reference, including eye-, head-, torso-, shoulder-, arm- and hand-centred coordinates [1,2,11]) can be differentially affected by neglect. The extent to which these different coordinates are truly independent is not yet clear [12].

Allocentric: Spatial position can also be coded in object-centred coordinates that are not dependent on the lateral position of the observer. Clinical studies have reported lateralised deficits that are spatially defined in terms of one object's position relative to another object. Alternatively, the left side of an object may be ignored irrespective of the object's position in relation to the patient [13]. Convincing evidence for selective damage to object-based frames of reference can be found in the drawing and copying performance of neglect patients [14] (see Box 1). Furthermore, object-centred coding that involves the intrinsic order of object parts (e.g. written words have a specified sequence of letters) has been reported. This form of coding was elegantly demonstrated by Caramazza and Hillis [15] in a left-brain-damaged patient with right-neglect dyslexia. When reading, her errors were always located on the last letters of the word irrespective of whether words were presented horizontally, vertically or even mirror-reversed.

Selective impairments of imaginal representation

Left lateralized breakdown in imaginal representations without corresponding deficits in perceptual-motor

performance (and vice versa) has also been found [16]. This double dissociation challenges Kosslyn's claim that perceptual and imagery processes share the same mental operations and neural structures [16,17].

Elucidating the neuropsychological structure of space

Although Euclidian space extends seamlessly to infinity in three dimensions, space for embodied creatures, such as ourselves, can plausibly be divided into three fundamental regions: personal space, peripersonal space, and extrapersonal space [5]. Personal space is the space of the body surface: the space on which one can feel a touch or a jab, the space within which one can comb one's hair or scratch an itch. Peripersonal space is space within arm's reach, the space in which one picks up a cup or washes a shirt. Extrapersonal space is space that is beyond arm's reach unless one brings it within peripersonal space by moving there or by deploying a tool. In the absence of such recalibration, one can orient the eyes toward an object in extrapersonal space, point to it, or throw something at it.

Although this trichotomy of spaces sounds reasonable, the relevant questions are: does the human brain represent these spaces in a distinct fashion and can the study of patients with visuospatial neglect speak to the issue? [18]. Evidence for a neurobiological distinction between peripersonal (near) and extrapersonal (far) space had already been obtained some twenty years ago in monkey [19]. Unilateral ablation of the frontal eye field (area 8) produces inattention to objects in contralesional far space, whereas unilateral ablation of frontal area 6 results in inattention to objects in contralesional near space. More recently, a wide range of dissociations has been reported between left neglect in personal, peripersonal and extrapersonal space in patients with right hemisphere lesions [16] (see Box 2).

Personal space

Neglect of left personal space can occur without neglect of left peripersonal space [20,21]. Typical manifestations of left personal neglect include failure to shave or groom the left side of the face, failure to adjust spectacles on the left side, and failure to notice the position of the left limbs and use them appropriately even when no significant motor weakness is present. By contrast, the ability to use left personal space without difficulty can be seen in the context of severe left neglect of peripersonal space as assessed by visual search tasks where the targets are displayed within arm's reach [20]. This double dissociation of personal and peripersonal neglect suggests that distinct neuronal circuits underlie how the two spaces are represented in the human brain.

Peripersonal and extrapersonal space

Similar double dissociations have been discovered between left neglect in peripersonal and in extrapersonal space. When lines of constant visual angle are bisected by laser pen in near versus far space, some patients show accurate performance in far space but a significant rightward deviation in near space, [22,23] whereas other patients show the reverse dissociation: far left neglect without near

Box 1. Attention and frames of reference

The debate as to whether figure is segregated from background preattentively, or whether attention is first directed to specific candidate regions of the image was informed by studies of neglect. In an elegant experiment using displays with an internal boundary located between two differently coloured regions and controlling for eye movements, Driver, Baylis and Rafal [71] showed that a brain-injured patient with visual neglect was able to perform normal segmentation of an image into figures and background. Marshall and Halligan [72] reported a patient with severe neglect who could perceive subjective contours and use lateral symmetry as a cue to figure-ground segregation (Fig. 1). Figure and ground regions could be modified by drawing the patient's attention to different regions of the image.

Different frames of reference

When copying, neglect patients typically draw the right side of the scene without noticing the incompleteness of the left side [73]. Because unilateral spatial neglect is observed under conditions where movements of the eyes and head are permitted, early accounts assumed that the term 'left' referred to left of the patient's midline. But although the body midline is one of the most important frames of reference, other reference frames can be involved [11,74]. What is interesting about Fig. II (a) is that, here, the patient has not missed out the left side of the overall scene, but rather the respective left sides of the two objects present [14,75]. Double dissociations between the two frames of reference show that they can function independently of each other [76,77].

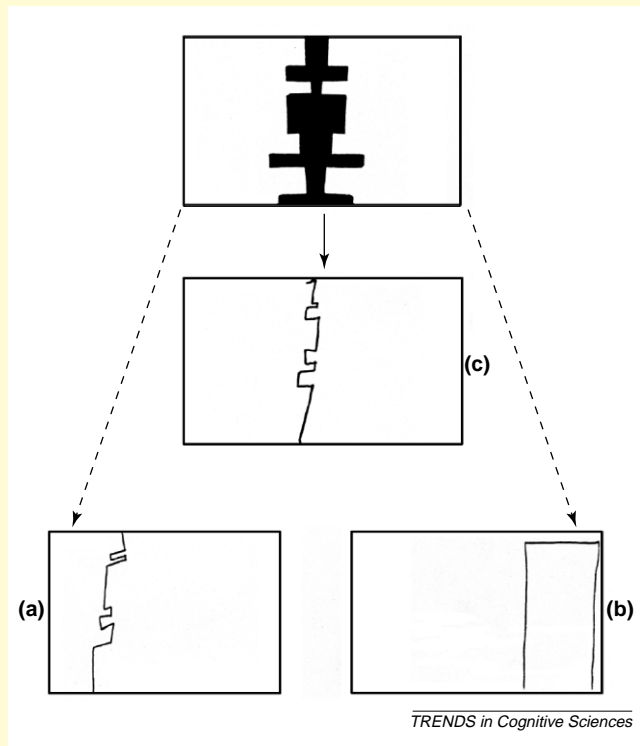


Fig. 1. Preserved figure-ground segregation in visual neglect. When asked to copy the display shown, only the right side of the black figure was ever drawn (c). Nonetheless, the left side of this same object could be accurately copied (a) when it was cued as the right side of the left white sub-figure (previously 'ground'). Copies of the left side for the right white sub-figure (previously 'ground') always showed neglect of the details of the contour (b).

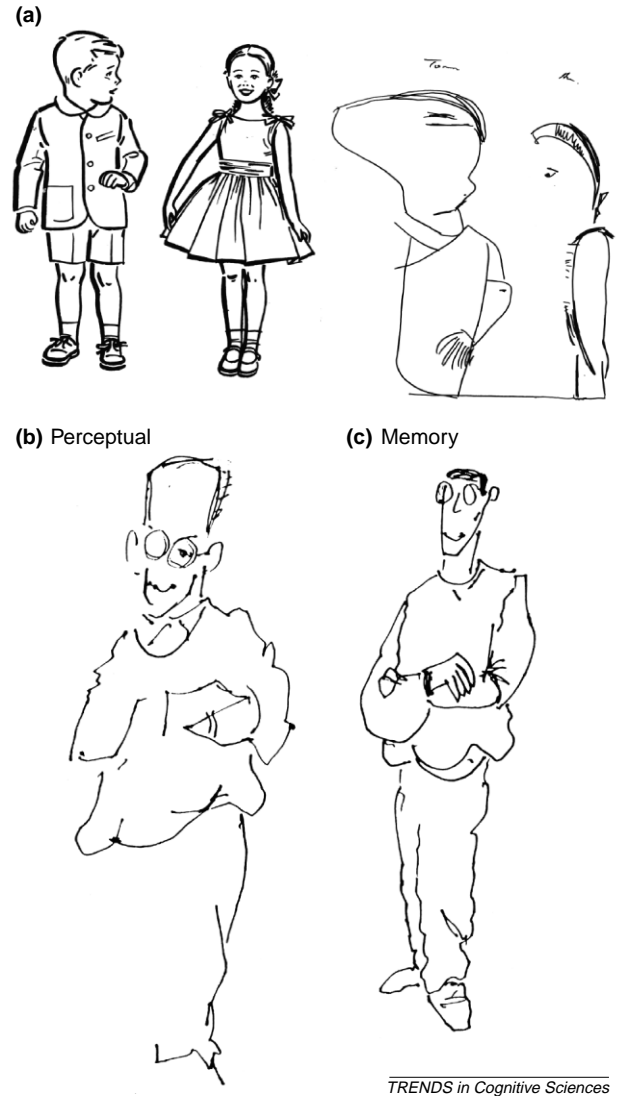


Fig. II. (a) Different frames of reference. Here, the neglect patient has copied the drawing on the left, but omitted the left-hand side of each figure in the drawing, rather than simply the whole left figure. This is evidence of a dissociation between two frames of reference. (b,c) When another neglect patient was requested to draw a subject from life the sketch showed clear evidence of lateralised neglect (b), but when asked to draw from memory, the same patient produced a complete representation.

Differences between copying and drawing from memory

After suffering a right-hemisphere stroke, patient NS, previously a professional cartoonist, typically omitted left-sided details when copying. Requested to draw from memory a free-hand sketch of the first author, NS drew a complete representation (Fig. IIc). However, when requested to draw the same subject from life the sketch showed clear evidence of lateralised neglect (Fig. IIb). In the perceptual task right-sided details had greater attentional salience and hence elicits left neglect. By contrast, the mental image of the same subject resulted in a complete composition (see also [17]).

left neglect [24,25]. These positive findings contrast with an early failure to show dissociations between near and far left neglect when perceptual tasks with no manual component were used [26]. Accordingly, it might seem that acting in a particular spatial domain is required for

distinct neuronal representations of near or far space to become active.

A recent study that used both perceptual and motor versions of line bisection in near and far space argues against this view [27]. The same patients were tested in all

Box 2. The representation of different spatial domains

Previous studies of line bisection in patients with right hemisphere lesions have shown that bisection performance can differ between near and far space. Thus left visuospatial neglect in near (peripersonal) space has been found with normal performance in far (extrapersonal) space [22]. Contrary to this, severe left neglect in far (extrapersonal) space with good performance in near (peripersonal) space has also been reported [24]. These dissociations in patients with left neglect have been investigated with horizontal line bisection and a laser pen, so that both the action required to bisect, and the visual angle subtended by the stimulus line, can be held constant in near and far space.

This issue has been investigated with functional neuroimaging in healthy controls [78]. Consistent with the previous neuropsychological double dissociation of line bisection accuracy in near and far space, the findings indicated that pointing and bisection tasks performed in near space draw differentially upon left dorsal occipital cortex, left intraparietal cortex, left ventral premotor cortex, and left thalamus (Fig. 1). Performing the same tasks in far space differentially draws upon ventral occipital cortex bilaterally and medial temporal cortex bilaterally. These activations were additional to the occipital and parietal activations implicated in task performance in both near and far space.

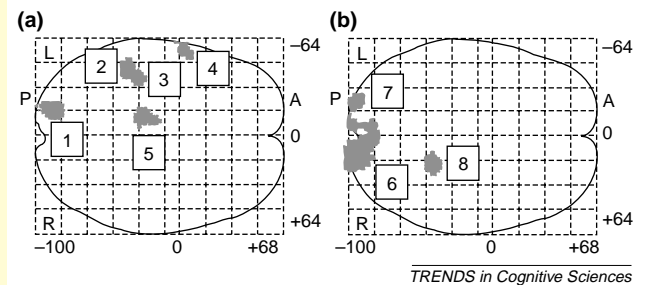


Fig. 1. (a) Relative rCBF increases associated with action in near space ($P < 0.001$). Transverse views are shown as through-projections onto representations of standard stereotaxic space. Areas within the dorsal stream of visuomotor processing are activated: the left dorsal occipital cortex (1), the left intraparietal cortex (2 and 3), the ventral premotor cortex (4), and the left thalamus (5). P, posterior; A, anterior; R, right; L, left. (b) Relative rCBF increases associated with action in far space ($P < 0.001$ uncorrected). Activations located in the ventral visuoperceptual processing stream were found: bilateral ventral occipital cortex (6 and 7) and the right medial temporal cortex (8).

conditions. In both the perceptual and the motor tasks, some patients showed near left neglect without far left neglect and others the reverse dissociation. Thus different accuracy of performance between spatial domains can be revealed by purely perceptual tasks. Furthermore, the patients showed similar degrees of impairment on the motor and the perceptual versions of line bisection.

Extending peripersonal space by tool use

Although the limits of peripersonal (grasping) space are normally determined by the reach of the arms, that space can be physically extended by the use of rigid tools [28,29]. How, in these circumstances, does the brain encode this enlarged peripersonal space? Berti and Frassinetti [23] reported a patient who showed clear left neglect on a range of tasks (including bisection) in near space but little or no neglect on bisection when using a laser pointer to operate in far space. Yet when a long stick was substituted for the laser pointer, significant left neglect was again manifest. That is, when the patient reached into far space with a rigid tool, far space became re-mapped as near space. The reverse re-mapping was found in a patient who showed a more complex pattern of neglect, including neglect of far right space but not near right space [30]. In this case, use of a rigid implement to point to objects in far right space improved performance: the tool extended the boundary of intact near space processing.

Neuroanatomical basis of spatial neglect: lesion studies in humans

Current knowledge concerning the neuroanatomical basis of spatial unilateral neglect in humans, and, by implication, of conscious spatial representation and directed attention comes from two main sources: (1) the traditional anatomo-clinical correlation between the site of the cerebral lesion and the behavioural deficit; (2) the more recently developed temporary interference with the function of specific cerebral areas, induced by transcranial

magnetic stimulation (TMS). Anatomo-clinical correlation studies (permanent structural lesions) and TMS (temporary functional lesions) provide information as to the cerebral areas necessary to the execution of the task of interest, and, therefore, about the core neuroanatomical basis of the relevant function. This type of anatomo-behavioural inference is complemented by the results from cerebral activation studies, using PET or fMRI (see next section). Not all the cerebral areas activated (or deactivated) by a given task are necessary to the execution of it, representing instead a more redundant neural network. The integration of lesion and activation findings will however reveal the complete functional neuroanatomy of spatial unilateral neglect and spatial cognition [31].

Lesion studies in brain-damaged patients

Anatomo-clinical data suggest that lesions of the posterior parietal lobe are the most frequent anatomical correlate of spatial unilateral neglect. More precisely, the crucial area is the inferior parietal lobule (supramarginal gyrus, Brodmann's area, BA 40) at the temporo-parietal junction [32,33]. Lesions localised more posteriorly in the occipital regions, or more superiorly in the superior parietal lobule bring about visual field deficits [32] or a deficit of reaching (optic ataxia), without neglect [34]. Other cerebral areas, damage to which can be associated with neglect, include the superior temporal gyrus [35], the lateral premotor cortex (BA 44 and 6), [32] and a number of subcortical regions (thalamus, basal ganglia, white matter fibre tracts) [32,36,37].

These lesion data, largely based on behavioural tasks requiring the motor exploration of visual space, such as target cancellation (see Fig. 2) suggest that a neural network including the frontal premotor cortex and the posterior-inferior parietal regions, at the temporo-parietal junction, provide a main neural basis for spatial cognition. The recent suggestion [35] that damage to the superior temporal gyrus constitutes the neural correlates of 'pure

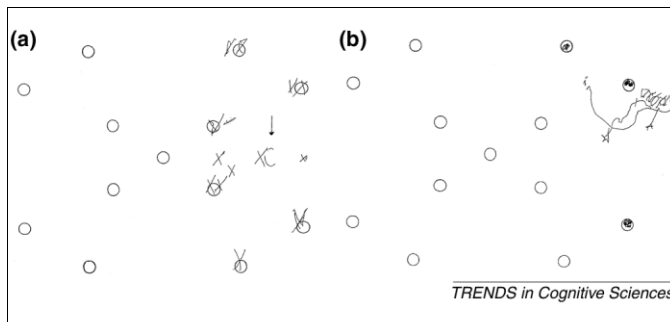


Fig. 2. Perseveration in circle cancellation by right-brain-damaged patients with left spatial neglect. This graphic perseveration, which occurs in the ipsilesional right side of space, includes the addition of lines, for example: (a) one target circle, which is successively crossed out; and more complex behaviour, such as unsolicited spontaneous drawings, for example: (b) a hen. This productive, rather than defective, manifestation of neglect illustrates its composite nature. (Reproduced from Ref. [67] with permission of Elsevier Science)

neglect' – as opposed to damage to the inferior parietal region, which would bring about an impure form of neglect, that is, neglect associated with a primary visual sensory deficit (left hemianopia) – is largely unwarranted. In that study [35] patients with damage clustering in the right inferior-posterior parietal regions, and patients with lesions in the right superior temporal gyrus all exhibited left neglect, as assessed by the same visuo-motor exploratory tasks.

The logical conclusion that may be drawn from these empirical data is that damage to the superior temporal gyrus, *in addition to* damage to the other brain regions discussed earlier, can bring about left neglect [36].

Studies that have measured regional cerebral blood flow and metabolism in patients with neglect show that the extent of the cerebral dysfunction, as revealed by hypoperfusion or hypometabolism, is much wider than the cerebral areas destroyed by the lesion, and involves areas far removed but connected with the damaged regions [37,38]. These findings indicate that the neural basis of neglect, and of spatial cognition, comprises a number of connected cortical and subcortical brain regions (Fig. 3). The network disrupted in many neglect patients spares the occipital and the primary sensory/motor cortices, suggesting that damage to peripheral sensorimotor loops does not account for the core pathological mechanisms of neglect.

In anatomico-clinical correlation studies, neglect has been assessed by a variety of clinical tests, including target cancellation, line bisection, drawing and copying tasks. Although these are standard clinical tools used to detect the disorder, they were not designed to tease apart more specific mechanisms that might underlie the defective performance of a particular patient – for example, perceptual deficits, such as impaired access to conscious experience, or premotor disorders, such as the defective ability to execute movements towards the neglected side of space [1,5]. The association between these pathological mechanisms of neglect and damage to specific parts of the network discussed earlier is accordingly much less definite: nonetheless, some premotor aspects of neglect may be associated with frontal damage, some perceptual aspects with parietal lesions [39].

Ipsilesional graphic perseveration in cancellation tasks

is more frequent in right brain-damaged neglect patients with subcortical or frontal damage [40], and can be reflected in the release of complex motor behaviour (see Fig. 2). Temporoparietal lesions extending more posteriorly in the occipital regions and causing hemianopia may bring about a more severe impairment on line bisection tasks [41]. Finally, the anatomical correlates of extinction to double simultaneous stimulation in right-brain-damaged patients do not entirely overlap with those of neglect. Subcortical and primary sensory regions are more frequently involved, with a relative sparing of inferior-posterior parietal cortex [42]. This differential lesion pattern suggests that the two disorders, which may occur in isolation, have discrete underlying pathological mechanisms.

The anatomical evidence reviewed above concerns left neglect and right brain damage. Right spatial neglect associated with left brain damage is both less severe and less frequent. The anatomical evidence is therefore much less definite, although it suggests fronto-parietal damage plays a role [1,5].

Interference studies

Experiments using TMS in normal subjects have recently corroborated the view that damage to right posterior parietal cortex is the main pathological correlate of spatial neglect. Right parietal repetitive (r)TMS induces a rightward bias in judgments about the symmetry of pre-bisected lines, which mimics the rightward error in line bisection, committed by right-brain-damaged patients with left neglect; left parietal rTMS, by contrast, has no detectable effects on this task [43,44]. rTMS of the left or of the right parietal lobe produces visual extinction of contralateral stimuli during double simultaneous stimulation [45]. Extinction refers to the elicited phenomenon

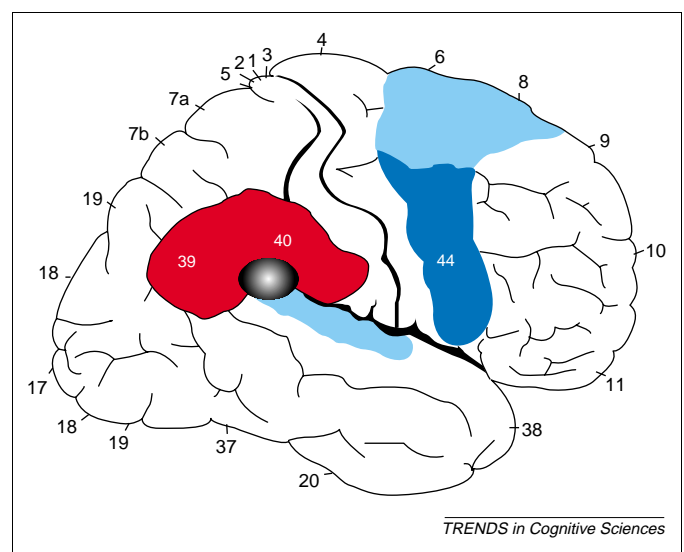


Fig. 3. Cortical anatomical correlates of unilateral visuospatial neglect. Most anatomico-clinical correlation studies (e.g. [68–70]) show that the lesion responsible involves the right inferior parietal lobule (Brodmann areas, BA 39 and 40, highlighted in red), particularly the supramarginal gyrus, at the temporo-parietal junction (black–grey area). Neglect after right frontal damage is less frequent and usually associated with lesions to the frontal premotor cortex, particularly to the more ventral parts (BA 44 and ventral BA 6, dark blue area). Neglect can also be associated with damage to the more dorsal and medial regions of the frontal premotor cortex, and to the superior temporal gyrus (lighter blue areas).

Box 3. The effect of instructional set on a simple bisection judgement task

In this fMRI experiment normal volunteers were asked to assess whether pre-transected horizontal lines were correctly bisected or not [79]. They made these judgments (indicated by a button press) under two distinct task instructions:

- (1) 'Are the line segments on either side of the transection mark of equal length?'
- (2) 'Is the transection mark in the centre of the line?'

Comparison of line-centre judgments (relative to line-length comparisons) revealed differential activation in the lingual gyrus bilaterally and anterior cingulate cortex (Fig. 1a), whereas explicit line-length comparisons (relative to line-centre judgments) differentially activated superior-posterior parietal cortex (Fig. 1b). Activations common to both task instructions included inferior parietal cortex bilaterally and right temporo-occipital cortex (not shown in the figure). The differential activation of superior posterior parietal cortex following length comparison instructions suggests that explicit estimations of spatial extent were implicated. The differential activation of bilateral occipital cortex following line-centre judgments suggests that the centre of a line (or centre of mass of the display) is extracted at an early stage of visual processing.

In a related clinical study of unilateral neglect, 32 patients were requested to bisect a line and then to judge whether their transections were placed 'at the centre of the line' and to judge 'which segment of the

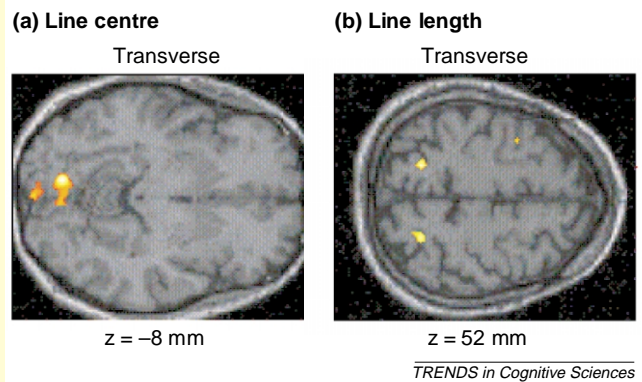


Fig. 1. fMRI activations in normal subjects during judgments of the centre of a line (a), and the comparison of line lengths either side of a transection mark (b).

transected line (left or right) was the longer' [80]. The study showed no association between accuracy of judgement under the two instructions and is fully consistent with the neurophysiological results described above for normal volunteers.

whereby patients fail to report one of two stimuli in conditions of simultaneous stimulation, although perception of single stimuli (in either visual hemispace) is preserved [1]. Contralateral neglect and extinction to double simultaneous stimulation are temporarily improved by rTMS delivered to the unaffected hemisphere [46]. Accordingly, one mechanism underlying these disorders might be an imbalance in activity of the two sides of the brain, caused by unilateral damage [47]. That imbalance would be temporarily reduced by TMS interfering with the prevailing activity of the undamaged hemisphere.

Neural systems underlying spatial processing

Human functional neuroimaging highlights the importance of posterior parietal cortex (PPC) for attending to spatial locations (space-based attention) or features of visual stimuli (object-based attention) [48]. More importantly, these techniques extend the information provided by lesion studies: where neuropsychological studies are limited by large lesion sizes and remote effects, functional imaging studies allow a more detailed specification of the areas involved in the cognitive operations underlying some of the core deficits of neglect. Furthermore, new analysis techniques allow the assessment of functional and effective connectivity among neuronal systems [49].

Voluntary orienting versus target detection in human PPC

Concurring with electrophysiological single-unit recordings, functional neuroimaging studies indicate that parietal and frontal cortex mediate the covert and overt allocation of attention. Cortical activation occurs primarily in the areas around the intraparietal sulcus (IPS) when a location is attended before visual target presentation, whereas the right temporoparietal junction (TPJ) is activated when a target is detected, particularly at an

unattended location [50]. The former system is thus involved in preparing and applying goal-directed (top-down) selection for stimuli and responses, whereas the latter system is 'specialized for the detection of behaviourally relevant stimuli, particularly when the stimuli are salient or unexpected and could thus work as a "circuit breaker" for the dorsal system, directing attention to salient events' [51].

Defective awareness of contralesional sensory input, namely the inability to detect and to report events in the contralesional portion of space, is a main feature of spatial unilateral neglect. These findings are consistent with neuropsychological studies [52]: damage to the parietal lobe produces a specific deficit in the disengage operation when a target is contralateral to the lesion. The effects of brain injury on disengagement of attention seem to be unique to parietal lobe lesions and do not occur with frontal or temporal controls [52].

Taken together, these studies confirm the close connection between parietal lobes and selective attention originally suggested by macaque single cell recordings. More specifically, they indicate a specific mechanism underlying the effects of parietal lesions seen in clinical neurology.

The human PPC and spatial information processing

Using variants of the line bisection task and the landmark task (see Box 3) it has been repeatedly demonstrated that visuospatial judgments activate right parietal cortex along the IPS [53]. Right PPC is thus not only involved in target detection and orienting but also in spatial processing *per se*. Furthermore, right inferior parietal cortex and left TPJ have also been implicated in directing attention to global and local aspects of hierarchically organized visual stimuli: In a divided attention task, the number of target switches between local and global and information covaried with temporo-parietal activation [54].

Functional imaging studies that explored the neurophysiology of visual imagery are also consistent with lesion studies of representational neglect [1,2]. Using a variant of the 'mental clocks' paradigm originally devised by Paivio [55] and fMRI, Trojano *et al.* [56] found significant activation of posterior parietal cortex (PPC) bilaterally in healthy volunteers. A related study [57] confirmed that both parietal lobes were involved in the mental clock task and further showed, by time-resolved fMRI, that left PPC was mainly involved in image generation and right PPC in image inspection and analysis.

Human PPC and the egocentric reference frame

As indicated earlier, spatial positions can be referenced to the subject's body or to objects in the environment. Thus egocentrically-referenced and allocentrically-referenced sensory information needs to be represented and integrated [58]. In both macaques and humans, PPC contributes to the computation of spatial reference frames [58]. Functional imaging data show increased neural activity in a predominantly right hemispheric fronto-parietal system when normal subjects perform tasks that involve the computation of the subjective mid-sagittal plane [59] or judgments of the location of a visual stimulus with respect to either their body or another object [48].

PPC and directing visual awareness

We are not passive recipients of information projected onto the retina but rather actively influence the perceptual processes: functional imaging studies demonstrate attentional modulation of neural activity in retinotopically organized visual cortex both in the presence and in the absence of any visual modulation [60]. This effect is stronger in frontal and parietal areas suggesting that they exercise top-down control to increase or decrease the neural activity in early visual processing areas. The frontal and parietal areas are also implicated when attention is directed to global or local aspects of hierarchically organized visual stimuli [54] or the colour, shape, or velocity of objects [61].

In good accord with these findings, the loss of conscious awareness of left space in neglect implies that the inferior parietal cortex and its connections contribute to visual experience [62]. Interestingly, interference from distractors that appear either close in time (backwards masks) or close in space (flanking masks) to a target engages the cortex around IPS [63]. Such interference may contribute to extinction and neglect when damage to posterior parietal cortex reduces the processing capacity of the attentional system.

A recent study using healthy volunteers provides an influential account of contralesional extinction on bilateral stimulation after unilateral brain injury [64]. An extinction-like pattern was found behaviorally, subjects reporting characters in one hemifield less accurately when competing characters appeared in the other hemifield. Differences in neural activity for unilateral minus bilateral conditions revealed greater activation of striate and extrastriate areas for stimuli presented without competing stimuli in the other hemifield. Thus, simultaneous bilateral stimulation led to a significant reduction

in response by spatiotopic visual cortex contralateral to a particular stimulus.

Another fMRI experiment similarly demonstrated that when multiple stimuli are present simultaneously in one visual field, their cortical representations within the object recognition pathway interact in a competitive, suppressive fashion [65]. Furthermore, directing attention to one of the stimuli counteracted the suppressive influence of nearby stimuli. These data not only provide physiological support for theories of interhemispheric rivalry in the intact human brain, but also demonstrate that such competition can occur within one hemisphere (corresponding to the attentional gradients observed in neglect patients). Furthermore, these effects are already occurring at early levels of perceptual processing. These neurophysiological data help to explain the phenomenon of extinction: a stimulus might have sufficient impact when being processed on its own, but the simultaneous presence of another stimulus can reduce its impact and hence lead to a loss of awareness for one of the two stimuli.

Conclusions

The neuropsychological syndrome of unilateral spatial neglect has become a strong and increasingly relevant tool to dissect the functional and anatomical architecture of the systems involved in spatial cognition. There is now definite evidence that spatial cognition involves a complex set of independent, although related, systems, which are likely to have discrete neuroanatomical correlates. Recent investigations of patients with spatial neglect have clear implications for our understanding of the manifold processes subserving spatial cognition. In particular, the evidence is compelling that pre-attentive, non-conscious processing is extensive and involves many domains.

A second issue concerns the distinction between different reference frames and regions of space (corporeal, within and outside hand reach), which appears not to be rigid but modulated instead by the physical extent of the effector used for action. This provides a strong case for an interaction between perception and action.

Finally, the neuroanatomical basis of these manifold spatial processes is complex and multi-componential. The traditional lesion data from brain-damaged patients are now complemented by functional neuroimaging experiments and by transient, experimentally induced dysfunctions in normal subjects. These multiple approaches are providing patterns, admittedly incomplete as yet, of converging evidence.

Acknowledgements

J.C.M. and P.W.H. are supported by the UK Medical Research Council; G.R.F. is supported by the Deutsche Forschungsgemeinschaft. G.V.'s research is being supported in part by a MIUR-Cofin Grant.

References

- 1 Vallar, G. (1998) Spatial hemineglect in humans. *Trends Cogn. Sci.* 2, 87–97
- 2 Karnath, H-O. *et al.* (eds) (2002) *The Cognitive and Neural Bases of Spatial Neglect* Oxford University Press
- 3 Halligan, P.W. and Marshall, J.C. (2001) Graphic neglect—more than the sum of the parts. *Neuroimage* 14, S91–S97

- 4 Stone, S.P. *et al.* (1998) Unilateral neglect: a common but heterogeneous syndrome. *Neurology* 50, 1902–1905
- 5 Robertson, I.H. and Halligan, P.W. (1999) *Spatial Neglect: A Clinical Handbook for Diagnosis and Treatment*, Erlbaum
- 6 Kanwisher, N. and Wojciulik, E. (2000) Visual attention: insights from brain imaging. *Nat. Rev. Neurosci.* 1, 91–100
- 7 Driver, J. and Vuilleumier, P. (2001) Perceptual awareness and its loss in unilateral neglect and extinction. *Cognition* 79, 39–88
- 8 Vuilleumier, P. (2000) Faces call for attention: evidence from patients with visual extinction. *Neuropsychologia* 38, 693–700
- 9 Shulman, M.B. *et al.* (2002) Triangular backgrounds shift the bias of line bisection performance in hemispatial neglect. *J. Neurol. Neurosurg. Psychiatry* 72, 68–72
- 10 Daini, R. *et al.* (2002) Exploring the syndrome of spatial unilateral neglect through an illusion of length. *Exp. Brain Res.* 144, 224–237
- 11 Beschin, N. *et al.* (1997) Left of what? The role of egocentric coordinates in neglect. *J. Neurol. Neurosurg. Psychiatry* 63, 483–489
- 12 Behrmann, M. and Geng, J.J. (2002) What is 'left' when all is said and done/spatial coding and hemispatial neglect. In *The Cognitive and Neural Bases of Spatial Neglect* (Karnath, H.O. *et al.*, eds), pp. 85–100, Oxford University Press
- 13 Umiltà, C. (2000) Mechanisms of attention. In *Handbook of Cognitive Neuropsychology* (Rapp, B., ed.), pp. 135–158, Psychology Press
- 14 Halligan, P.W. and Marshall, J.C. (1993) When two is one: a case study of spatial parsing in visual neglect. *Perception* 22, 309–312
- 15 Caramazza, A. and Hillis, A.E. (1990) Spatial representation of words in the brain implied by studies of a unilateral neglect patient. *Nature* 346, 267–269
- 16 Bartolomeo, P. (2002) The relationship between visual perception and visual mental imagery; a reappraisal of the neuropsychological evidence. *Cortex* 38, 357–378
- 17 Kosslyn, S.M. (1994) *Image and Brain: The Resolution of the Imagery Debate*, MIT Press
- 18 Previc, F.W. (1998) The neuropsychology of 3-D space. *Psychol. Bull.* 124, 123–164
- 19 Rizzolatti, G. *et al.* (2000) Spatial neglect: neurophysiological bases, cortical circuits and theories. In *Handbook of Neuropsychology* (Boller, F. and Grafman, J., *et al.* eds), pp. 503–537, Elsevier
- 20 Cocchina, G. *et al.* (2001) The fluff test: a simple task to assess body representational neglect. *Neuropsychol. Rehab.* 11, 17–31
- 21 Guariglia, C. and Antonucci, G. (1992) Personal and extrapersonal space: a case of neglect dissociation. *Neuropsychologia* 30, 1001–1009
- 22 Halligan, P.W. and Marshall, J.C. (1991) Left neglect for near but not far space in man. *Nature* 350, 498–500
- 23 Berti, A. and Frassinetti, F. (2000) When far becomes near: remapping of space by tool use. *J. Cogn. Neurosci.* 12, 415–420
- 24 Vuilleumier, P. *et al.* (1998) Near and far visual space in unilateral neglect. *Ann. Neurol.* 43, 406–410
- 25 Barrett, A.M. *et al.* (2000) Attentional grasp in far extrapersonal space after thalamic infarction. *Neuropsychologia* 38, 778–784
- 26 Pizzamiglio, L. *et al.* (1989) Visual neglect for far and near extrapersonal space in humans. *Cortex* 25, 471–477
- 27 Pitzalis, S. *et al.* (2001) Influence of the radial and vertical dimensions on lateral neglect. *Exp. Brain Res.* 136, 281–294
- 28 Iriki, A. *et al.* (1996) Coding of modified body schema during tool use by macaque postcentral neurones. *Neuroreport* 7, 2325–2330
- 29 Berti, A. *et al.* (2001) Coding of far and near space in neglect patients. *Neuroimage* 14, S98–S102
- 30 Ackroyd, K. *et al.* (2002) Widening the sphere of influence: using a tool to extend extrapersonal visual space in a patient with severe neglect. *Neurocase* 8, 1–12
- 31 Vallar, G. (2000) The methodological foundations of human neuropsychology: studies in brain-damaged patients. In *Handbook of Neuropsychology* (Boller, F. and Grafman, J., eds), pp. 305–344, Elsevier
- 32 Vallar, G. and Perani, D. (1986) The anatomy of unilateral neglect after right-hemisphere stroke lesions. A clinical/CT-scan correlation study in man. *Neuropsychologia* 24, 609–622
- 33 Leibovitch, F.S. *et al.* (1998) Brain-behavior correlations in hemispatial neglect using CT and SPECT: the Sunnybrook Stroke Study. *Neurology* 50, 901–908
- 34 Perenin, M-T. (1997) Optic ataxia and unilateral neglect: clinical evidence for dissociable spatial functions in posterior parietal cortex. In *Parietal Lobe Contributions to Orientation in 3D Space* (Their, P. and Karnath, H.O., eds), pp. 209–308, Springer-Verlag
- 35 Karnath, H.O. *et al.* (2001) Spatial awareness is a function of the temporal not the posterior parietal lobe. *Nature* 411, 950–953
- 36 Marshall, J.C. *et al.* (2002) Spatial awareness: a function of the posterior parietal lobe? *Cortex* 38, 253–257
- 37 Perani, D. *et al.* (1993) Left and right hemisphere contribution to recovery from neglect after right hemisphere damage—an [18F]FDG pet study of two cases. *Neuropsychologia* 31, 115–125
- 38 Pizzamiglio, L. *et al.* (1998) Recovery of neglect after right hemispheric damage: H2(15)O positron emission tomographic activation study. *Arch. Neurol.* 55, 561–568
- 39 Vallar, G. (2001) Extrapersonal visual unilateral spatial neglect and its neuroanatomy. *Neuroimage* 14, S52–S58
- 40 Na, D.L. *et al.* (1999) Motor perseverative behavior on a line cancellation task. *Neurology* 52, 1569–1576
- 41 Daini, R. *et al.* (2002) Exploring the syndrome of spatial unilateral neglect through an illusion of length. *Exp. Brain Res.* 144, 224–237
- 42 Vallar, G. *et al.* (1994) Anatomical correlates of visual and tactile extinction in humans: a clinical CT scan study. *J. Neurol. Neurosurg. Psychiatry* 57, 464–470
- 43 Fierro, B. *et al.* (2000) Contralateral neglect induced by right posterior parietal rTMS in healthy subjects. *Neuroreport* 11, 1519–1521
- 44 Fierro, B. *et al.* (2001) Timing of right parietal and frontal cortex activity in visuospatial perception: a TMS study in normal individuals. *Neuroreport* 12, 2605–2607
- 45 Hilgetag, C.C. *et al.* (2001) Enhanced visual spatial attention ipsilateral to rTMS-induced 'virtual lesions' of human parietal cortex. *Nat. Neurosci.* 4, 953–957
- 46 Oliveri, M. *et al.* (2001) rTMS of the unaffected hemisphere transiently reduces contralesional visuospatial hemineglect. *Neurology* 57, 1338–1340
- 47 Kinsbourne, M. (1993) Orientational bias model of unilateral neglect: evidence from attentional gradients within hemispace. In *Unilateral Neglect: Clinical and Experimental Studies* (Robertson, I.H. and Marshall, J.C., eds), pp. 63–86, Erlbaum
- 48 Fink, G.R. *et al.* (1997) Space-based and object-based visual attention: shared and specific neural domains. *Brain* 120, 2013–2028
- 49 Buchel, C. and Friston, K. (2000) Assessing interactions among neuronal systems using functional neuroimaging. *Neural Netw.* 13, 871–882
- 50 Corbetta, M. *et al.* (2000) Voluntary orienting is dissociated from target detection in human posterior parietal cortex. *Nat. Neurosci.* 3, 292–297
- 51 Corbetta, M. and Shulman, G.L. (2002) Control of goal-directed and stimulus-driven attention in the brain. *Nat. Rev. Neurosci.* 3, 201–215
- 52 Posner, M.I. *et al.* (1984) Effects of parietal injury on covert orienting of attention. *J. Neurosci.* 4, 1863–1874
- 53 Fink, G.R. *et al.* (2000) 'Where' depends on 'what': a differential functional anatomy for position discrimination in one- versus two-dimensions. *Neuropsychologia* 38, 1741–1748
- 54 Fink, G.R. *et al.* (1997) Neural mechanisms involved in the processing of global and local aspects of hierarchically organized visual stimuli. *Brain* 120, 1779–1791
- 55 Paivio, A. (1978) Comparisons of mental clocks. *J. Exp. Psychol. Hum. Percept. Perform.* 4, 61–71
- 56 Trojano, L. *et al.* (2002) Coordinate and categorical judgements in spatial imagery: an fMRI study. *Neuropsychologia* 40, 1666–1674
- 57 Formisano, E. *et al.* (2002) Tracking the mind's image in the brain: I. Time-resolved fMRI during visuospatial mental imagery. *Neuron* 35, 185–194
- 58 Behrmann, M. (2000) In *The New Cognitive Neurosciences* (Vol. 2) (Gazzaniga, M.S., ed.), pp. 651–666
- 59 Vallar, G. *et al.* (1999) A fronto-parietal system for computing the egocentric spatial frame of reference in humans. *Exp. Brain Res.* 124, 281–286
- 60 Ress, D. *et al.* (2000) Activity in primary visual cortex predicts performance in a visual detection task. *Nat. Neurosci.* 3, 940–945
- 61 Corbetta, M. *et al.* (1991) Selective and divided attention during visual discriminations of shape color, and speed: functional anatomy by positron emission tomography. *J. Neurosci.* 11, 2383–2402
- 62 Driver, J. and Mattingley, J.B. (1998) Parietal neglect and visual awareness. *Nat. Neurosci.* 1, 17–22

- 63 Marois, R. *et al.* (2000) Neural correlates of the attentional blink. *Neuron* 28, 299–308
- 64 Fink, G.R. *et al.* (2000) Neural consequences of competing stimuli in both visual hemifields: a physiological basis for visual extinction. *Ann. Neurol.* 47, 440–446
- 65 Kastner, S. *et al.* (1998) Mechanisms of directed attention in the human extrastriate cortex as revealed by functional MRI. *Science* 282, 108–111
- 66 Thaiss, L. and De Bleser, R. (1992) Visual agnosia: a case of reduced attentional 'spotlight'? *Cortex* 28, 601–621
- 67 Rusconi, M.L. *et al.* (2002) Is the intact side really intact? Perseverative responses in patients with unilateral neglect: a productive manifestation. *Neuropsychologia* 40, 594–604
- 68 Vallar, G., *et al.* Neglect syndromes: the role of parietal cortex. In *The Parietal Lobe* (Spencer, D., ed.), Lippincott Williams & Wilkins (in press)
- 69 Heilman, K.M. *et al.* (1994) Localization of lesions in neglect and related disorders. In *Localization and Neuroimaging in Neuropsychology* (Kertesz, A. *et al.*, eds), pp. 495–524, Academic Press
- 70 Vallar, G. (1993) The anatomical basis of spatial hemineglect in humans. In *Unilateral Neglect: Clinical and Experimental Studies* (Robertson, I.H. and Marshall, J.C., eds), pp. 27–59, Erlbaum
- 71 Driver, J. *et al.* (1992) Preserved figure-ground segregation and symmetry perception in visual neglect. *Nature* 360, 73–75
- 72 Marshall, J.C. and Halligan, P.W. (1994) The Yin and the Yang of visuo-spatial neglect: a case study. *Neuropsychologia* 32, 1037–1057
- 73 Ishiai, S. *et al.* (1996) Mechanisms of unilateral spatial neglect in copying a single object. *Neuropsychologia* 34, 965–971
- 74 Behrmann, M. and Tipper, S.P. (1999) Attention accesses multiple reference frames: evidence from visual neglect. *J. Exp. Psychol. Hum. Percept. Perform.* 25, 83–101
- 75 Driver, J. and Halligan, P.W. (1991) Can visual neglect operate in object-centred co-ordinates? An affirmative single-case study. *Cogn. Neuropsychol.* 8, 475–496
- 76 Ota, H. *et al.* (2001) Dissociation of body-centered and stimulus-centered representations in unilateral neglect. *Neurology* 57, 2064–2069
- 77 Walker, R. (1995) Spatial and object-based neglect. *Neurocase* 1, 371–384
- 78 Weiss, P.H. *et al.* (2000) Neural consequences of acting in near versus far space: a physiological basis for clinical dissociations. *Brain* 123, 2531–2541
- 79 Fink, G.R. *et al.* (2002) Task instructions influence the cognitive strategies involved in line bisection judgements: evidence from modulated neural mechanisms revealed by fMRI. *Neuropsychologia* 40, 119–130
- 80 Seki, K. *et al.* (1999) Unassociated responses to two related task demands: a negative factor for improvement of unilateral spatial neglect. *Neuropsychologia* 37, 75–82

TICS online – making the most of your personal subscription

- High quality printouts (from PDF files)
- Links to other articles, other journals and cited software and databases

All you have to do is:

- Obtain your subscription key from the address label of your print subscription
- Then go to http://www.trends.com/free_access.html
- Click on the large 'Click Here' button at the bottom of the page
- You will see one of the following:
 - (1) A BioMedNet login screen. If you see this, please enter your BioMedNet username and password. If you are not already a member please click on the 'Join Now' button and register. Once registered you will go straight to (2) below.
 - (2) A box to enter a subscription key. Please enter your subscription key here and click on the 'Enter' button.
- Once confirmed, go to <http://tics.trends.com> and view the full-text of **TICS**

If you get an error message please contact Customer Services (info@current-trends.com) stating your subscription key and BioMedNet username and password. Please note that you do not need to re-enter your subscription key for **TICS**, BioMedNet 'remembers' your subscription. Institutional online access is available at a premium. If your institute is interested in subscribing to print and online please ask them to contact ct.subs@rbi.co.uk